

Outcome of Five Dogs that had a **HYDRAULIC URETHRAL OCCLUDER** for the Control of Urinary Incontinence

by Clare R. Gregory, DVM, DACVS and
Gilbert T. Robello, DVM, DACVS

Hydraulic urethral occlusion employs a silicon cuff placed around the proximal urethra. The cuff is filled with variable amounts of saline to provide mechanical obstruction to urine flow through the urethra. The amount of saline in the cuff, and the degree of resistance to flow, is adjusted using a subcutaneous injection port placed on the inner thigh.

The use of hydraulic urethral occluders to control urinary incontinence in dogs was pioneered by Dr. Chris Adin. While at the University of Florida, Dr. Adin performed studies showing the filling and pressure effects of the cuff and fitted and tested the cuffs in

cadaver specimens (Am J Vet Res 2006; 67:1453-8). Dr. Adin has performed multiple occluder implants and recently published a long-term follow-up on four dogs that received the occluder for the control of urinary incontinence (Vet Surgery 2009; 38: 747-53). The period following surgery ranged from 26 to 30 months. All dogs had been, and were continent since the placement of the occluder. One dog had to have the subcutaneous injection port removed due to infection, but remained continent with the occluder left in place. All dogs are still continent over three years following surgery with no further complications.

Hydraulic urethral occluders are used to control incontinence associated with ovariectomy and primary urethral sphincter incompetence. Previous techniques for the control of incontinence depended on stretching or expanding soft tissues to provide resistance to flow. These included colposuspension, urethral in folding techniques, and collagen injections. Soft tissues under stretch or expansion will relax (the "face-lift" dilemma). This means that many of these procedures would initially be successful, but over time the soft tissues would relax and remodel and incontinence would return. At this point, the procedure would have to be redone, augmented by another procedure, or the patient was returned to medical therapy. The obstruction to flow provided by the hydraulic occluder is mechanical and

therefore static. The effect lasts as long as the occluder is in place. At this point there is no evidence of physical injury to the bladder/proximal urethra following placement of the occluder.

Following correction of ectopic ureters, approximately 50% of dogs remain incontinent due to urethral sphincter incompetence. Hydraulic urethral occluders can be used to control incontinence in these dogs as well. Occluders have been used to control incontinence in both female and male dogs.

Candidates for placement of a hydraulic urethral occluder should have a thorough examination of the urinary tract. Incontinence due to ectopic ureter has to be ruled out as a cause. The data base should include the history and duration of the incontinence, a complete blood count, a serum chemistry panel, and a urinalysis and urine bacterial culture. Abdominal ultrasound and abdominal radiographs +/- contrast can be used to evaluate the size, shape and position of the kidneys, ureters and bladder. Cystourethroscopy can be performed to confirm the location of the ureteral openings and look for anatomic abnormalities in the urethra and vestibule. Urethral pressure profiles can help with the confirmation of urethral sphincter incompetence. A hooded vulva may contribute to incontinence, particularly right after urination. An epispioplasty or vulvar fold resection can be performed to correct this problem. It is optimal if urinary tract infections are treated and resolved prior to surgery. This helps to determine the effectiveness of the occluder following surgery.

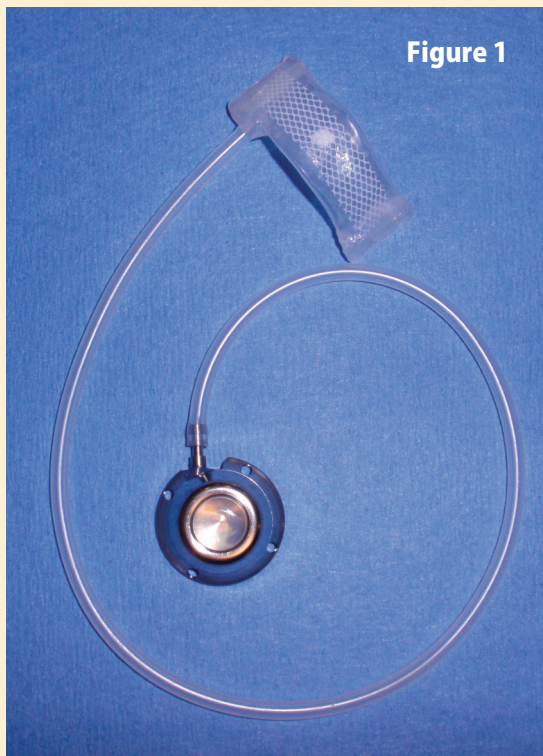


Figure 1

OCCLUDER IMPLANTED

Urinary Incontinence

Many dogs that have received the hydraulic occluder had poor or failed control with medical management of phenylpropanolamine or estrogen therapy. In our experience, dogs that have the occluder placed no longer require medical therapy.

Following placement of the occluder, the dogs are monitored overnight in the hospital. Prior to discharge it is important to confirm that the dogs can urinate. Phenylpropanolamine is discontinued on the day of surgery. In the initial two weeks following surgery, the dogs tend to urinate quite frequently. I believe this is due to the effect of the presence of the occluder on the proximal urethra and that the urinary bladder has to develop more of a reservoir function. Bladders of incontinent dogs tend to be thin and weak. With increased resistance provided by the occluder, the bladder wall thickens and the capacity increases.

The abdominal sutures are removed at two weeks following surgery. If the incontinence is not controlled, a small volume of saline is added to the cuff via the subcutaneous port in the thigh. No anesthesia is required. The dog is observed until it is seen to urinate. The dog is rechecked if incontinence continues, and further volumes of saline can be added to the occluder.

We have implanted occluders in five dogs for the control of urethral sphincter incompetence.

Siena, 4.5-year old, female spayed, Labrador. Siena has been incontinent since her spay operation at six months of age. She had failed three trials of diethylstilbestrol, and was poorly

controlled with phenylpropanolamine. Surgery was performed 11/18/2009.

Indio, 4-year old, female spayed, Labrador. Indio was spayed at six months of age and became incontinent at 2.5 years of age. Indio would pool urine when she slept. She became agitated and aggressive when administered phenylpropanolamine. Surgery was performed 1/21/2010.

Brook, 4-year old, female spayed, German shepherd cross. Brook had been incontinent since she was spayed, but also demonstrated submissive urination since birth. Surgery was performed 4/1/2010.

Ginger, 4-year old, female spayed, Wheaton Terrier. Ginger had been incontinent since birth. Previous examinations at another medical center (cystoscopy/computed tomography) suggested a left ectopic ureter, but the incontinence was intermittent. Cystoscopy and surgical exploration found the ureteral openings to be in a normal position. The bladder was gourd-shaped and located in the pelvic canal.

Ato, 5-year old, female spayed, Japanese Akita. Ato was adopted from a rescue shelter and the client lives in Kobe, Japan. Ato was incontinent while sleeping. Surgery was performed 6/18/2010 in Igaueno, Japan.

All dogs became continent immediately after surgery. None had difficulty urinating, but initially, frequent urination was common. No dog is receiving medical treatment for incontinence and all have normal activity. Brook will still posture to

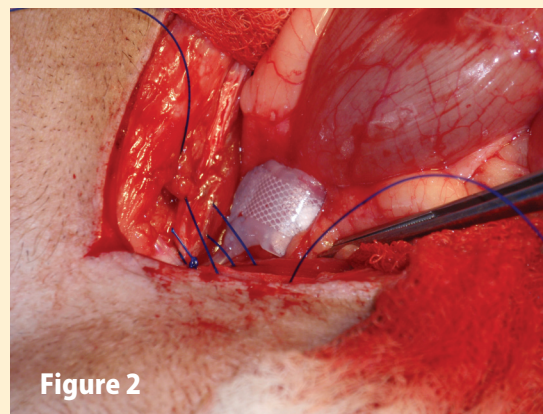


Figure 2

submissively urinate, but seldom produces urine. At this point, it has not been necessary to add or remove saline from any occluder. On July 23, 2010, Siena presented for incontinence following urination and mucus discharge from the vulva. Siena had experienced a marked weight gain since surgery and had developed a severely hooded vulva. Urine retention appeared to occur after urination and Siena was still continent at all other times. Urinalysis and culture were unremarkable, and vaginal cytology was normal. The incontinence and mucus discharge were attributed to mechanical obstruction by the vaginal hood. Current treatment is weight loss.

Hydraulic urethral occluders appear to offer a new and highly successful option for the control of urinary incontinence in the dog. The technique offers long-term control of incontinence with a single procedure. No medical management is necessary. The occluders appear to offer a superior surgical option to previous methods for the control of incontinence.

Figure 1. Hydraulic Urethral Occluder and Injection Port

Figure 2. Hydraulic Urethral Occluder placed around the proximal urethra

Contact: Dr. Clare R. Gregory, PetCare Veterinary Hospital, 1370 Fulton Road, Santa Rosa, California, 95401. Telephone: 707-579-5900. Email: cgregory_4@wavecable.com, and VCA AllCare Animal Referral Center, 18440 Amistad Street, Fountain Valley, California, 92708. Telephone: 714-963-0909